

increased uptake in the head of left femur and suspicion of AVN in the left head of femur was raised (Figure 1). She was advised MRI of hip joints by the treating physician, which showed hyper-intense signals with marrow changes in the head of left femur and acetabulum, suggestive of skeletal metastatic lesion (Figure 2). Follow-up bone scan after 1 year showed an abnormal increased uptake in the right parietal region of the skull, few ribs, and uptake in left head of femur, extending up to the trochanteric region with findings compatible with skeletal metastasis (Figure 3).

Discussion

AVN was first reported by Munro in 1,738 people, with poorly understood pathogenesis [4]. Extravascular pressure on small arteries and intravascular thrombosis are regarded as the common proposed pathogenesis [5]. Common sites involved head of femur, humerus,

mandible, scaphoid, and talus bones. The head of femur is the most common site of AVN [6]. AVN of the head of femur is believed to be a leading causing of hip replacements, accounting for almost 10% of all hip replacements [7]. Non-traumatic causes of AVN are usually underappreciated, mostly involving young patients due to prolonged use of high dose steroids and cancer chemotherapeutic drugs [8,9]. Thrombosis in the arteries is commonly seen in cancer patients and may lead to AVN in the long run if there is involvement of the feeding vessel to the head of femur [10]. AVN may be asymptomatic, although it predominantly presents as local discomfort in the relevant joint, then progressing to painful restrictions of movements causing functional disability [11].

Diagnosis of AVN is usually done with routine plain radiographs, ^{99m}Tc-MDP BS, Single Photon Emission computed tomography coupled with low dose CT scan (SPECT/CT) and magnetic resonance imaging (MRI). MRI is usually regarded as the gold standard for diagnosis of AVN, while BS is regarded as a primary tool for skeletal survey for skeletal metastasis in patients with malignant disorders [2,12].

Plain radiographs may not be helpful in the diagnosis of early AVN. In the advance stages of AVN, the plain radiograph may show mild demineralization to degeneration/flattening of the femoral head. SPECT/CT hybrid imaging can also be helpful in diagnosis of AVN. SPECT images may show avascular focus involving femoral head later replaced by increased activity in remodeling phase, with CT scan showing sub-chondral lucencies and sclerosis during the remodeling phase, before collapse of femoral head [13].

Skeletal metastatic lesions primarily involve the axial skeleton, with less involvement of appendicular skeleton.

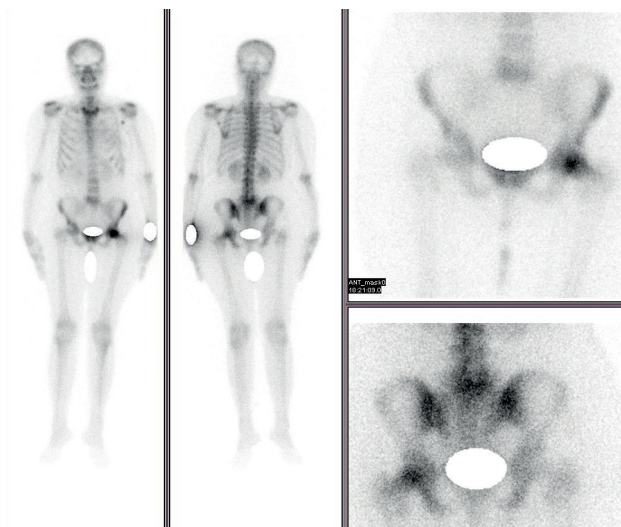


Figure 1. ^{99m}Tc-MDP Bone scintigraphy showing focal increased uptake in the head of left femur with suspicion of AVN left head of femur.

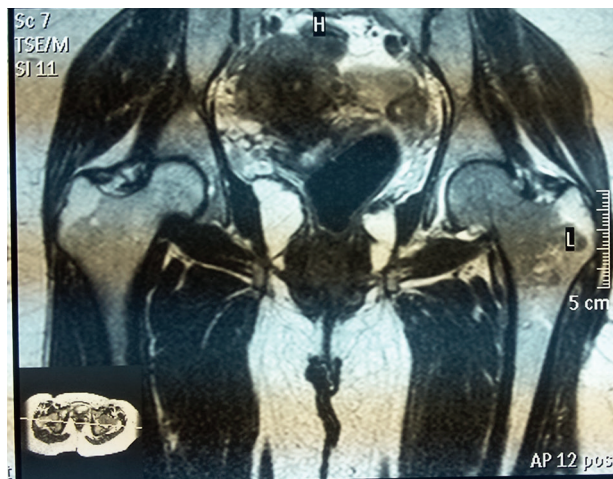


Figure 2. MRI (T1) of the bone and hip joints showing marrow signal changes in the head of left femur suggestive of a skeletal metastatic lesion.

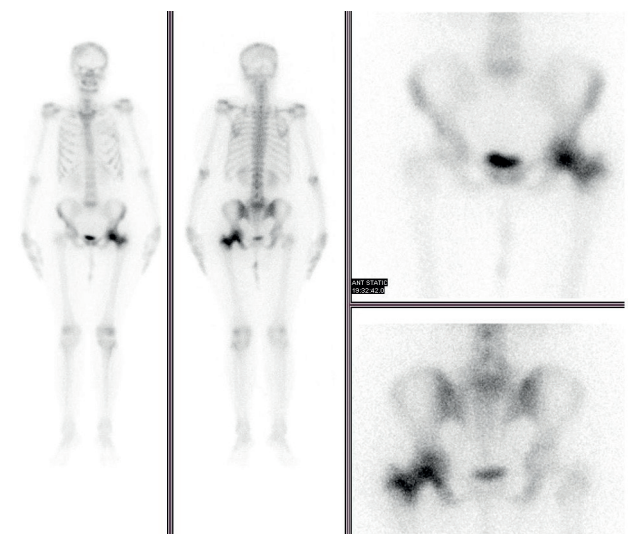


Figure 3. Follow-up ^{99m}Tc-MDP bone scintigraphy after 1 year showing an abnormal increased uptake in the right parietal region of skull and few ribs with an uptake in the left head of femur extending up to trochanteric region and compatible with skeletal metastasis.

The spine, pelvis, rib cage, and ends of long bones are regarded as the common sites of bone metastases due to high content of red marrow [14].

Bone scan is highly sensitive for osteoblastic bony lesions but has inherent low specificity [15]. All pathognomonic processes outlined by bone scan are analyzed by experts, based on experience and imaging atlas in mind. Based on their lifelong learning curves, and history of the patient with patterns, appearance and distribution of the lesions, they label a lesion as metastatic/malignant or non-metastatic/benign in nature. In case of ambiguity, further characterization usually needs correlative radiological imaging or histopathological confirmation. MRI showed hyper-intense signals with marrow changes consistent with a metastatic lesion involving the head and neck of the left femur rather than AVN [16]. This diagnosis was confirmed by longitudinal follow-up. Bone scan done after 1 year confirmed that a lesion in the head of femur was not AVN, i.e., no change in head of femur and hip joint space. Along with this, the appearance of multiple new lesions and extension of the focal lesion in the head of femur to neck/trochanteric region of femur confirmed it to be a skeletal metastatic disease.

Conclusion

A solitary skeletal metastatic lesion in the head of femur is a rare finding. In the presence of local symptoms with focal uptake in femoral head, AVN remains at the top of differential diagnosis. However, probability of skeletal metastatic lesion must always be considered in patients with known history of carcinoma. Bone scan is a primary tool for skeletal metastatic survey due to high sensitivity for osteoblastic response but exhibits low specificity in relation to disease-specific pathognomonic findings. MRI must be considered in such cases as a safe, non-invasive, and easily available option for further characterization of solitary lesions.

What is new?

Both skeletal metastasis and AVN show osteoblastic response when imaged with ^{99m}Tc-MDP BS. A solitary osteoblastic lesion in the head of femur on bone scan turning out to be a skeletal metastatic lesion is a very rare finding, making it a unique case not reported in the literature previously. They are totally different pathologies with different lines of treatment, as one is benign and other is malignant. In our case, a solitary osteoblastic lesion in the head of femur with local symptoms favored the AVN head of femur which on further workup with MRI turned out to be a metastatic lesion, causing a total change in the line of management. It shows the importance of correlative imaging for proper diagnosis.

Acknowledgment

The authors acknowledge all the nuclear medicine staff.

List of Abbreviations

AVN	Avascular necrosis
BS	Bone scan
MDP	Methylene diphosphonate
MRI	Magnetic resonance imaging
SPECT/CT	Single photon emission computed tomography/CT scan

Consent for publication

Written informed consent was obtained from the patient.

Ethical approval

Ethical approval is not required at our institution to publish an anonymous case report.

Author details

Muhammad Iqbal¹, Muhammad Naeem², Zahra Ahmed¹, Syeda Hadia Najam¹, Muhammad Shahzad Afzal¹, Muhammad Babar Imran¹

1. Department of Nuclear Medicine, PINUM Cancer Hospital, Faisalabad, Pakistan
2. Department of Surgery, PINUM Cancer Hospital, Faisalabad, Pakistan

References

1. Zhang L, He Q, Zhou T, Zhang B, Li W, Peng H, et al. Accurate characterization of ^{99m}Tc-MDP uptake in extraosseous neoplasm mimicking bone metastasis on whole-body bone scan: contribution of SPECT/CT. *BMC Med Imaging*. 2019;19(1):44. <https://doi.org/10.1186/s12880-019-0345-1>
2. Agrawal K, Tripathy SK, Sen RK, Santhosh S, Bhattacharya A. Nuclear medicine imaging in osteonecrosis of hip: Old and current concepts. *World J Orthop*. 2017;8(10):747–53. <https://doi.org/10.5312/wjo.v8.i10.747>
3. Alqahtani MA, Korkoman AJ, Al-Gelban LOS, Alahmari AS, Motlag DS. Review of current concepts femoral of head osteonecrosis. *Egypt J Hosp Med*. 2018;70(8):1401–8. <https://doi.org/10.12816/0044656>
4. Mehdi I, Bahrani BA, Kamona A, Lawati FRA, Vennyor AJ. Non-traumatic avascular necrosis of femoral head in malignant disease: is it disease induced or treatment related? *J Pak Med Assoc*. 2018;68(2):310–7.
5. Shah KN, Racine J, Jones LC, Aaron RK. Pathophysiology and risk factors for osteonecrosis. *Curr Rev Musculoskelet Med*. 2015;8(3):201–9. <https://doi.org/10.1007/s12178-015-9277-8>
6. Large TM, Adams MR, Loeffler BJ, Gardner MJ. Posttraumatic avascular necrosis after proximal femur, proximal humerus, talar neck, and scaphoid fractures. *J Am Acad Orthop Surg*. 2019;27(21):794–805. <https://doi.org/10.5435/JAAOS-D-18-00225>
7. Moya-Angeler J, Gianakos AL, Villa JC, Ni A, Lane JM. Current concepts on osteonecrosis of the femoral head. *World J Orthop*. 2015;6(8):590–601. <https://doi.org/10.5312/wjo.v6.i8.590>
8. Harper PG, Trask C, Souhami RL. Avascular necrosis of bone caused by combination chemotherapy without corticosteroids. *Br Med J (Clin Res Ed)*. 1984;288(6413):267–8. <https://doi.org/10.1136/bmj.288.6413.267>
9. Salem KH, Brockert AK, Mertens R, Drescher W. Avascular necrosis after chemotherapy for haematological

- malignancy in childhood. *Bone Joint J.* 2013;95-B(12):1708–13. <https://doi.org/10.1302/0301-620X.95B12.30688>
10. Blann AD, Dunmore S. Arterial and venous thrombosis in cancer patients. *Cardiol Res Pract.* 2011;2011:394740. <https://doi.org/10.4061/2011/394740>
 11. Sen RK. Management of avascular necrosis of femoral head at pre-collapse stage. *Indian J Orthop.* 2009;43(1):6–16. <https://doi.org/10.4103/0019-5413.45318>
 12. Heindel W, Gübitz R, Vieth V, Weckesser M, Schober O, Schäfers M. The diagnostic imaging of bone metastases. *Dtsch Arztebl Int.* 2014;111(44):741–7. <https://doi.org/10.3238/arztebl.2014.0741>
 13. Stoica Z, Dumitrescu D, Popescu M, Gheonea I, Gabor M, Bogdan N. Imaging of avascular necrosis of femoral head: familiar methods and newer trends. *Curr Health Sci J.* 2009;35(1):23–8.
 14. O'Sullivan GJ, Carty FL, Cronin CG. Imaging of bone metastasis: an update. *World J Radiol.* 2015;7(8):202–11. <https://doi.org/10.4329/wjr.v7.i8.202>
 15. Agrawal A, Purandare N, Shah S, Rangarajan V. Metastatic mimics on bone scan: all that glitters is not metastatic. *Indian J Nucl Med.* 2016;31(3):185–90. <https://doi.org/10.4103/0972-3919.183605>
 16. Caranci F, Tedeschi E, Ugga L, D'Amico A, Schipani S, Bartollino S, et al. Magnetic resonance imaging correlates of benign and malignant alterations of the spinal bone marrow. *Acta Biomed.* 2018;89(1-S):18–33. <https://doi.org/10.23750/abm.v89i1-S.7008>

Summary of the case

1	Patient (gender, age)	Female, 40 years old
2	Final diagnosis	Skeletal metastatic lesion in the head of left femur
3	Symptoms	Pain in left hip with difficulty in walking
4	Medications	Nil
5	Clinical procedure	^{99m} Tc MDP bone scintigraphy, magnetic resonance imaging (MRI)
6	Specialty	Nuclear medicine